

Syndromic Ear Anomalies and Renal Ultrasounds

Raymond Y. Wang, MD*; Dawn L. Earl, RN, CPNP‡; Robert O. Ruder, MD§; and John M. Graham, Jr, MD, ScD‡

ABSTRACT. *Objective.* Although many pediatricians pursue renal ultrasonography when patients are noted to have external ear malformations, there is much confusion over which specific ear malformations do and do not require imaging. The objective of this study was to delineate characteristics of a child with external ear malformations that suggest a greater risk of renal anomalies. We highlight several multiple congenital anomaly (MCA) syndromes that should be considered in a patient who has both ear and renal anomalies.

Methods. Charts of patients who had ear anomalies and were seen for clinical genetics evaluations between 1981 and 2000 at Cedars-Sinai Medical Center in Los Angeles and Dartmouth-Hitchcock Medical Center in New Hampshire were reviewed retrospectively. Only patients who underwent renal ultrasound were included in the chart review. The literature was reviewed for the epidemiology of renal anomalies in the general population and in MCA syndromes with external ear anomalies. We defined a child as having an external ear anomaly when he or she had any of the following: preauricular pits and tags; microtia; anotia; or cup, lop, and other forms of dysplastic ears. A child was defined as having a renal anomaly if an ultrasound revealed any of the following: unilateral or bilateral renal agenesis; hypoplasia; crossed ectopia; horseshoe, pelvic, cystic kidney; hydronephrosis; duplicated ureters; megaureter; or vesicoureteric reflux.

Results. Because clinical genetics assessments were made by the same clinician at both sites (J.M.G.), data were combined. A total of 42 patients with ear anomalies received renal ultrasound; 12 (29%) of them displayed renal anomalies. Of the 12 patients with renal anomalies, 11 (92%) also received a diagnosis of MCA syndrome. Eleven of 33 patients (33%) with MCA syndromes had renal anomalies, whereas 1 of 9 patients (11%) with isolated ear anomalies had renal anomalies. Specific disorders seen were CHARGE association, Townes-Brocks syndrome, branchio-oto-renal syndrome, Nager syndrome, and diabetic embryopathy.

Conclusions. We conclude that ear malformations are associated with an increased frequency of clinically significant structural renal anomalies compared with the general population. This is due to the observation that auricular malformations often are associated with spe-

cific MCA syndromes that have high incidences of renal anomalies. These include CHARGE association, Townes-Brocks syndrome, branchio-oto-renal syndrome, Nager syndrome, Miller syndrome, and diabetic embryopathy. Patients with auricular anomalies should be assessed carefully for accompanying dysmorphic features, including facial asymmetry; colobomas of the lid, iris, and retina; choanal atresia; jaw hypoplasia; branchial cysts or sinuses; cardiac murmurs; distal limb anomalies; and imperforate or anteriorly placed anus. If any of these features are present, then a renal ultrasound is useful not only in discovering renal anomalies but also in the diagnosis and management of MCA syndromes themselves. A renal ultrasound should be performed in patients with isolated preauricular pits, cup ears, or any other ear anomaly accompanied by 1 or more of the following: other malformations or dysmorphic features, a family history of deafness, auricular and/or renal malformations, or a maternal history of gestational diabetes. In the absence of these findings, renal ultrasonography is not indicated. *Pediatrics* 2001;108(2). URL: <http://www.pediatrics.org/cgi/content/full/108/2/e32>; external ear, renal anomalies, ultrasound.

ABBREVIATIONS. BOR, branchio-oto-renal; MCA, multiple congenital anomaly; TBS, Townes-Brocks Syndrome; OAVS, oculoauriculovertebral spectrum; M/A, microtia/anotia; IDM, infant of a diabetic mother; TCS, Treacher Collins syndrome.

Many studies in the literature have noted a significant association between renal anomalies and various ear anomalies. Ear pits and tags, perhaps the most common minor ear malformation, occur with a frequency of 5 to 6 per 1000 live births.^{1,2} In the pediatric population, structural renal anomalies occur in 1 to 3 per 100 live births.³⁻⁵ Kohelet and Arbel⁶ noted that among 70 consecutive children who had isolated preauricular tags and were examined by renal ultrasonography, 6 (8.6%) had urinary tract abnormalities (5 with hydronephrosis, 1 with horseshoe kidney). In a separate study, among 69 children who had preauricular sinuses and were examined by renal ultrasound, 3 (4.3%) demonstrated renal anomalies (2 with hydronephrosis, 1 with branchio-oto-renal (BOR) syndrome and an absent left kidney and hypoplastic right kidney).⁷ A recent study³ of 32 589 consecutive live births, still births, and abortions over 10 years in the Mainz Congenital Birth Defect Monitoring System noted a 1.2% prevalence of renal anomalies. External ear anomalies of all types, including deformations from fetal constraint, were found in 19.0% of all newborns, compared with 23.8% in newborns

From the *University of California—Los Angeles, School of Medicine; ‡Department of Medical Genetics, Ahmanson Department of Pediatrics, Steven Spielberg Pediatric Research Center, Burns and Allen Research Institute, Cedars-Sinai Medical Center and Department of Pediatrics, University of California—Los Angeles; and §Department of Plastic and Reconstructive Surgery, Cedars-Sinai Medical Center, University of California—Los Angeles, Los Angeles, California.

Received for publication Jan 18, 2001; accepted Apr 9, 2001.

Reprint requests to (J.M.G.) 444 S San Vicente Blvd, Ste 1001, Mark Goodson Building, Cedars-Sinai Medical Center, Los Angeles, CA 90048.

PEDIATRICS (ISSN 0031 4005). Copyright © 2001 by the American Academy of Pediatrics.

TABLE 1. Percentages of Patients Seen at Cedars-Sinai and Dartmouth-Hitchcock Genetics Clinic With Renal Anomalies

Condition	<i>n</i>	Number With Renal Anomalies
Isolated ear anomaly	9	1 (11%)
MCA syndrome	33	11 (33%)
Total	42	12 (28.5%)

TABLE 2. Percentages of Patients With MCA Syndrome and Renal Anomalies

MCA Syndrome	<i>n</i>	Number With Renal Anomalies
CHARGE association	11	4 (36%)
OAVS	8	0 (0%)
BOR	7*	2 (29%)
Diabetic embryopathy	3	2 (66%)
Nager syndrome	3	2 (66%)
TBS	2	1 (50%)

*Several of these patients had been diagnosed previously as having Goldenhar syndrome because they had ear anomalies and epibulbar dermoids but were found subsequently to have linkage to the locus on 8q for EYA1.¹¹

with renal malformations, showing a slightly significant increased risk (odds ratio: 1.3) for renal anomalies in children with ear anomalies. After patients with syndromic diagnoses were excluded, there continued to be a strong association between auricular pits or cup ears and specific renal anomalies but no association between auricular tags and renal defects.³

Given the wealth of data indicating an association between ear and renal anomalies, the question is, "Should all children with ear anomalies receive renal ultrasonography?" We note that in children with ear anomalies, defects within all other organ systems occur with a frequency of 5% to 40%.^{1,2,8-10} We also note that ear and renal anomalies are components of many multiple congenital anomaly (MCA) syndromes. We present here data from our own genetics clinic regarding MCA syndrome diagnoses and the incidence of renal anomalies in patients with ear anomalies. We then review some of the more significant MCA syndromes with ear and renal anomalies.

METHODS

Charts of patients who had ear anomalies and were seen for clinical genetics evaluations at Cedars-Sinai Medical Center and Dartmouth-Hitchcock Medical Center between 1981 and 2000 were reviewed retrospectively. Only patients who underwent renal ultrasound were included in the chart review. Because clinical genetics assessments were made by the same clinician at both sites (J.M.G.), data were combined. The literature regarding MCA syndromes with ear anomalies was reviewed for epidemiology and reports of associated renal anomalies.

RESULTS

A total of 42 patients with ear anomalies received a renal ultrasound; 12 (29%) of them displayed renal anomalies. These results are summarized in Table 1. Of the 12 patients with renal anomalies, 11 (92%) also received a diagnosis of MCA syndrome. Percentages of renal anomalies in patients with an MCA syndrome are summarized in Table 2.

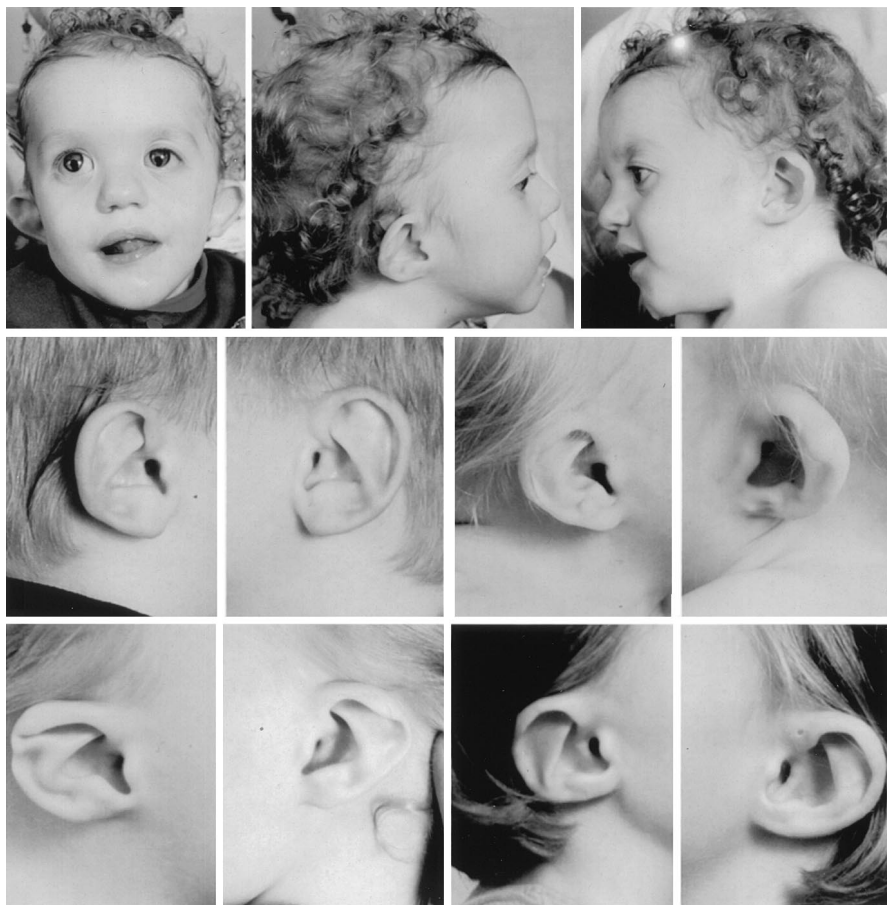
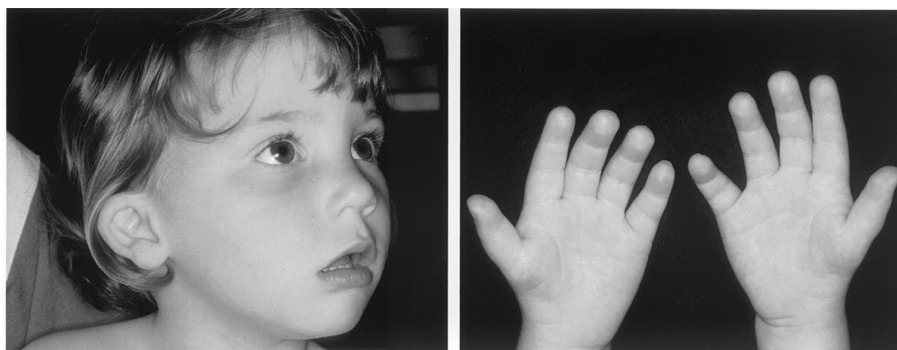
Fig 1. Top, typical child with CHARGE association illustrating low-set, posteriorly angulated ears with deficient cartilage and absent lobules. Note the iris colobomas and facial asymmetry in this patient. Bottom, 4 pairs of ears from children affected with CHARGE association demonstrating typical auricular dysmorphology and asymmetry.

Fig 2. TBS proband with mild auricular anomaly and hypoplastic thumbs (also had imperforate anus).



Clinical Syndromes With Associated Renal Anomalies

CHARGE Association/Syndrome

The majority of patients with CHARGE association represent sporadic occurrences in an otherwise normal family, with several reports supporting the possibility of autosomal dominant transmission. CHARGE association encompasses a wide spectrum of nonrandomly associated malformations, which include coloboma of iris or retina (80%–90%), heart defects (75%–80%; commonly conotruncal), atresia choanae (50%–60%), retarded growth (70%) and development (100%), genital hypoplasia (70%–80%), and ear defects (90%).¹¹ Figure 1 shows the triangular concha, prominent antihelix, and absent lobule characteristic of CHARGE ears. Renal anomalies occur in 15% to 25% of patients with CHARGE association. Also commonly seen are cleft lip and/or cleft palate (15%–20%) and tracheoesophageal fistula with esophageal atresia (15%–20%).¹¹

Recent reports document increasing evidence for a syndromic subset of patients within the spectrum of

CHARGE association displaying iris colobomas; choanal atresia; ear anomalies; and cranial nerve VII, IX, and X palsies with semicircular canal, cochlear, and temporal bone hypoplasia.^{12,13}

CHARGE association has superficial similarity to renal-coloboma syndrome, which is caused by mutations in the PAX2 gene, and also to DiGeorge sequence, which can be caused by deletion of chromosome 22q11, but these genetic abnormalities have been eliminated as causes of CHARGE association.¹⁴

Townes-Brocks Syndrome

Townes-Brocks syndrome (TBS), an autosomal dominant disorder, is caused by a mutation in the SALL1 transcription factor gene, which is expressed in the developing ear, limb buds, and excretory organs.¹⁵ Like many other autosomal dominant disorders, phenotypic expression is extremely variable but should include 2 or more of the following: bilateral external ear malformation (71%), hand malforma-

Fig 3. A second TBS proband demonstrating cup ears and hypoplastic thumbs (also had anteriorly placed anus and renal anomaly).

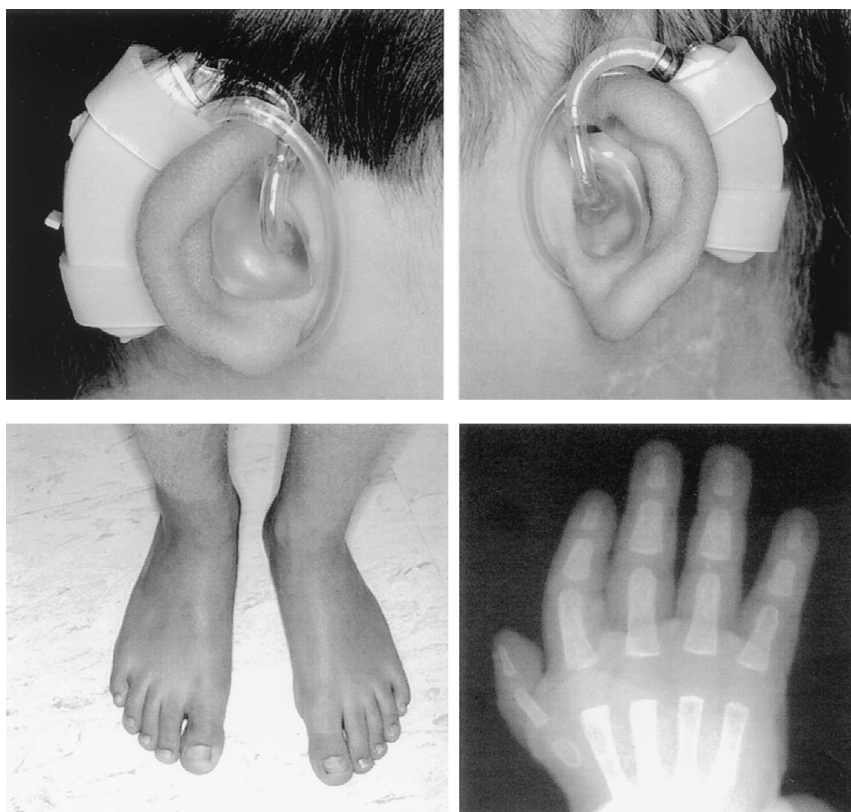
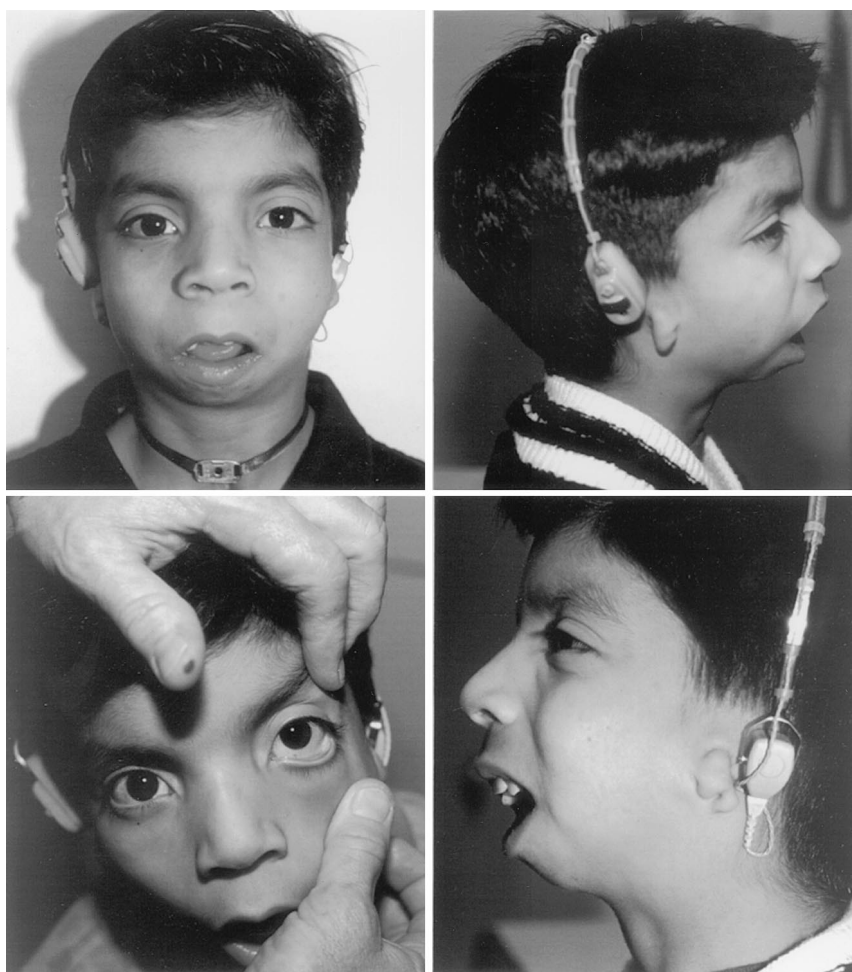

Fig 4. BOR proband (IV 19) whose initial diagnosis with familial Goldenhar syndrome because of severe micrognathia, conjunctival dermoids, and microtia. A branchial cleft cyst is evident on the left side of his neck, just above his tracheostomy collar.



tions (56%), and imperforate anus or rectovaginal/rectourethral fistula (47%).¹⁶

Ear defects, seen in Figs 2 and 3, can include microtia; overfolded superior helix; "satyr," "lop," or "cup" ear; and preauricular pits or tags; some published cases of *SALL1* mutations have had ears that resembled those seen in CHARGE association. Hand malformations consist mainly of preaxial ray defects, which can range from polydactyly of a biphalangal thumb to triphalangal thumb or thenar hypoplasia.¹⁷ Renal malformations have been noted in 27% of patients with TBS.¹⁶

Considerable similarity also exists between TBS and BOR ear anomalies, and this has been emphasized in the clinical literature,¹⁸ along with 1 report of a 3-generation family with overlapping features of TBS and oculoauriculovertebral spectrum (OAVS) with triphalangal thumbs, preauricular tags, abnormal tragus, overfolded superior helices, redundant anal skin in 2 individuals, micrognathia and macrosomia in 2 individuals, and epibulbar dermoids in all 3 individuals.¹⁹

Oculoauriculovertebral Spectrum

OAVS encompasses a broad variety and severity of defects in structures derived from the first and second branchial arches. It is predominantly sporadic in occurrence, with reports of autosomal dominant transmission in only 1% to 2% of cases.

Commonly observed malformations in OAVS include epibulbar dermoids (benign growths on the medial/lateral aspects of the cornea), preauricular tags and pits, microtia with accompanying conductive hearing loss, and small jaw resulting in an asymmetric face.²⁰ Patients with these features in conjunction with cleft lip and/or cleft palate and thoracic hemivertebrae are termed to have Goldenhar syndrome, a more severe form of OAVS.

The epidemiology of OAVS and isolated microtia/anotia (M/A) are similar, with a frequency of approximately 1.8 per 10 000 births; a male:female ratio of 3:2; and 70% to 90% unilateral involvement, of which 60% are right sided and 40% are left sided. Increasingly, isolated M/A is being considered as the mildest expression of OAVS.^{20,21}

The largest collected population of patients with OAVS was found to have a 5% prevalence (16 of 294) of genitourinary malformations, but this study included renal malformations with genital defects such as hypospadias, hydrocele, chordae penis, cryptorchidism, and scrotal anomalies.²⁰ Thus, it is unknown what portion of that 5% was accounted for by renal anomalies. Renal anomalies were noted in 4% of all cases of M/A.⁸⁻¹⁰

BOR Syndrome

BOR syndrome, an autosomal dominant disorder, is caused by a mutation in the eyeless (*EYA1*) tran-

scription factor gene and has a frequency of 1 in 40 000 live births. Approximately 60% of cases have branchial cysts or fistulas, usually found on the external lower third of the neck, at the median border of the sternocleidomastoid muscle (Fig 4), and 30% to 60% of patients with BOR have ear anomalies that range from severe microtia to small, lop or cupped ears with overfolded superior helices similar to TBS ears (Fig 5). Preauricular pits are present in 70% to 80% and sometimes can be the only external ear finding. At least 75% have conductive, sensorineural, or mixed hearing loss, and 12% to 20% have structural kidney anomalies.²²

BOR has extremely variable expression, and even within the same family, affected individuals show differing phenotypes (Fig 6). Some members have kidney malformations, whereas others may have malformations so subtle that imaging cannot identify them. There are conflicting reports as to whether branchio-oto (BO) syndrome is a variant of BOR syndrome; some studies of BO families show linkage to EYA1,²³ whereas others do not.^{24,25} Two other EYA1 homologs have been cloned, and it is possible that some cases of BO are caused by mutations in these other EYA genes or in other genes in the EYA signaling pathways.

Diabetic Embryopathy

Infants of diabetic mothers (IDMs) have been noted to have malformations in a wide variety of organ systems as a result of the direct and indirect teratogenic effects of hyperglycemia on the develop-

ing embryo. This is evidenced by both studies in animal models and the observation that the risk for fetal malformations increases with elevations in glycosylated hemoglobin.^{26,27} In addition to macrosomia, infants who are born to mothers who have either chronic or gestational diabetes are at increased risk for dysplastic ears (Fig 7), holoprosencephaly, spine/rib malformations such as caudal dysgenesis, and renal/urinary defects (Martínez-Frías ML, unpublished data).⁵ Other defects ascribed to IDMs include respiratory hypoplasia, cardiovascular defects, gastrointestinal tract atresia, oculoauriculovertebral sequence, and limb reduction.^{5,28}

Treacher Collins Syndrome

Treacher Collins syndrome (TCS) is an autosomal dominant condition caused by mutations in the *treacle* gene, the function of which has not been determined. TCS comprises mostly craniofacial abnormalities of structures derived from the first branchial arch, including downslanting palpebral fissures, lower lid colobomas, depressed cheekbones, bilateral microtia, conductive hearing loss, micrognathia, cleft palate, and pharyngeal hypoplasia. Renal anomalies are not recognized as part of this syndrome.^{29,30}

Nager Syndrome

Nager syndrome is a disorder whose craniofacial features are very similar to those of TCS. Mandibular hypoplasia tends to be more severe than that of TCS and commonly results in respiratory distress; however, limb defects, specifically preaxial anomalies

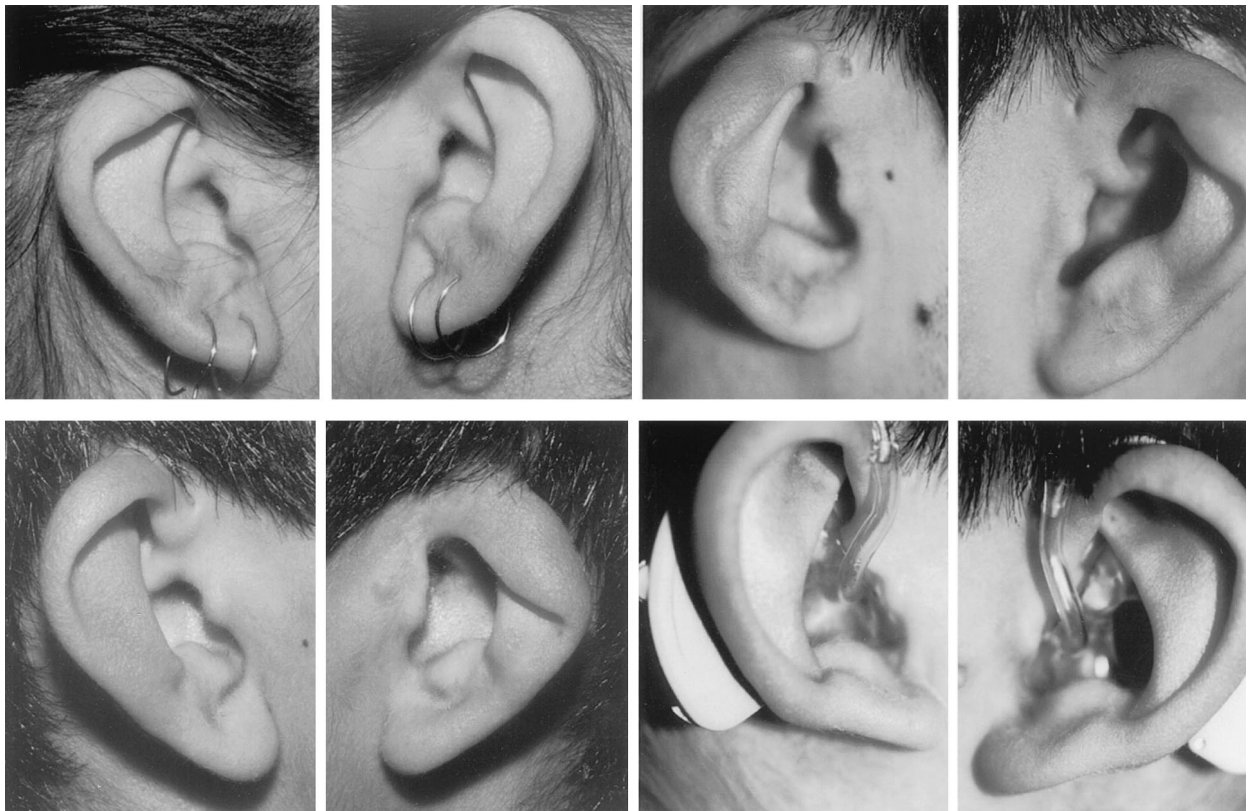


Fig 5. Ears of affected siblings (top, IV 10 and IV 11; bottom, IV 16 and IV 21) of the BOR proband in Fig 4 again showing marked variability in ear dysmorphology. Only patient IV 21 had a detectable renal anomaly (single kidney). Note the preauricular pits of IV 11.

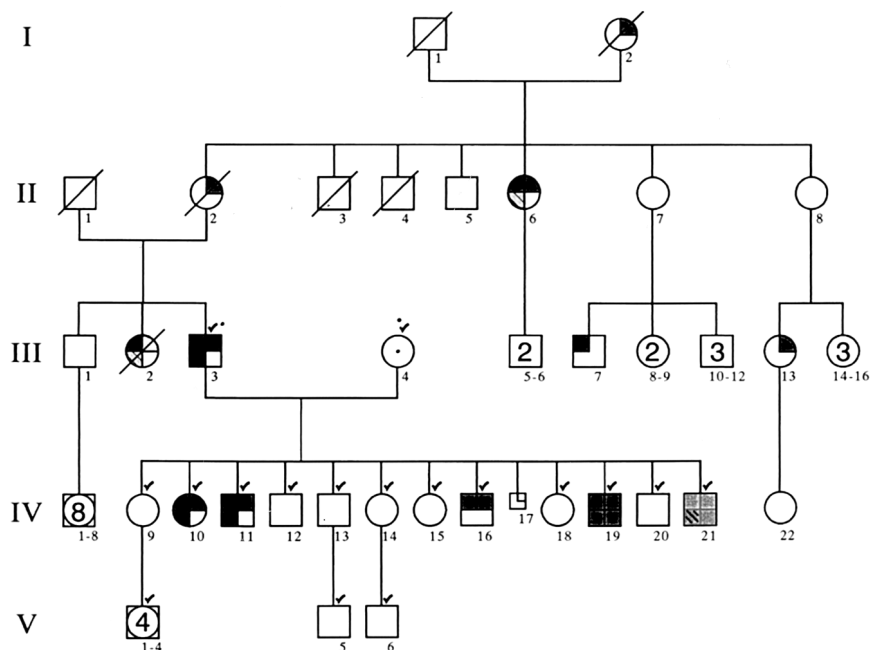


Fig 6. Pedigree of family in Fig 5 that demonstrated linkage to the EYA1 locus on 8q11 to 13. Note the marked variability in phenotypic expression.

Key to Symbols

		Branchial Cleft Cyst
		Ear Abnormality +/- Hearing Loss
		Epibulbar Dermoid Cyst
		History of Seizures
		Renal Anomalies
		Multiple Congenital Anomalies
		Examined by JG

(hypoplastic or absent thumbs and radii), are the principal distinguishing feature. Defects also can be seen in the lower extremities—hypoplastic halluces and other absent toes. Renal malformations were found in 7 of 78 (9%) of affected individuals.^{31–34} The mode of inheritance remains unclear; both autosomal dominant and autosomal recessive inheritance has been suggested.

Miller Syndrome

Miller syndrome is extremely rare, with only 18 reported cases in the literature. Like Nager syndrome, craniofacial features are similar to TCS, but lower-lid ectropion is much more pronounced in Miller syndrome than in the other facial dysostoses. The cardinal finding of Miller syndrome is ulnar limb deficiencies such as ulnar hypoplasia and fifth finger and/or toe agenesis or underdevelopment. Reflux and hydronephrosis were noted in 1 of the 18 cases (5.5%).³⁵

DISCUSSION

In 1946, Edith Potter's association of crumpled, flattened ears with bilateral kidney agenesis³⁶ led

pediatricians to routinely order renal ultrasounds in children with virtually any type of ear anomaly. Although there are many articles in the literature about this subject, no set of uniform standards exists for determining which types of ear anomalies require renal imaging. Population studies do show an increased incidence of renal malformations in children with ear anomalies. The Mainz Congenital Birth Defect Monitoring System study suggested that minor ear anomalies are extremely common and that pits and cup ears are more likely to be associated with renal defects than ear tags in an otherwise normal-appearing infant.³ This may reflect detection of sporadic cases of occult BOR. Ear and renal anomalies often are components of other MCA syndromes, particularly CHARGE association, TBS, Nager syndrome, Miller syndrome, and diabetic embryopathy. Table 3 summarizes the history and examination findings found in patients with these syndromes. A patient with isolated preauricular pit(s), cup ears, or an ear anomaly accompanied by positive findings in any of these areas should undergo a renal ultrasound to aid in diagnosis of these syndromes. Otherwise, a renal ultrasound is not recommended.

Fig 7. Two sporadic cases of lethal diabetic embryopathy with dysplastic ears. Top, case had vertebral defects and hypoplastic left heart. Bottom, case had rib and vertebral defects, Di-George sequence, single kidney, and pancreatic islet cell hyperplasia.

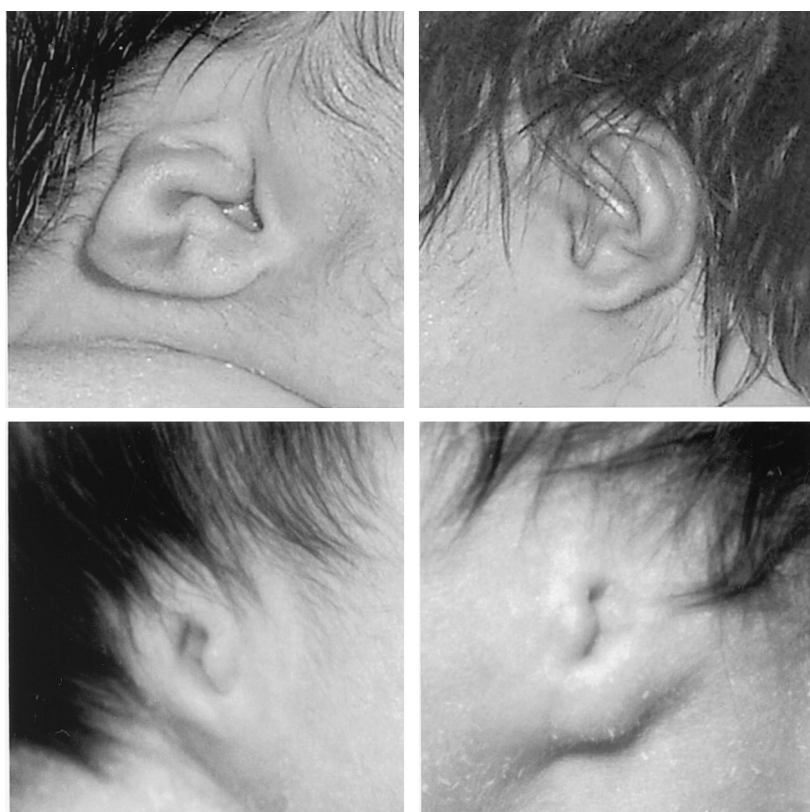

TABLE 3. Areas to Focus on in Initial Evaluation of a Patient With an External Ear Anomaly

Area	Findings
Birth history	Gestational diabetes mellitus (any class), teratogenic exposures
Family history	Ear anomalies, hearing loss
Craniofacial	Iris, lid, retinal colobomata; downslanting palpebral fissures with midface hypoplasia; preauricular pit(s); cup ears; hypoplasia of semicircular canals and cochlea; micrognathia
Neck	Branchial cleft sinuses or cysts
Cardiac	Murmurs suggesting congenital heart defects
Gastrointestinal	Imperforate anus, rectovaginal fistula, rectourethral fistula
Limbs	Abnormal palmar creases, polydactyly, missing 1st or 5th digits, bifurcated/triphalangeal thumbs, thenar hypoplasia

Finally, because of the profoundly deleterious effects of delayed diagnosis of hearing impairment on a child's communication and social development, audiologic testing and intervention are crucial in the workup of any child with an ear anomaly. A significant percentage of children (see Table 4) with ear anomalies have some degree of hearing loss, and early detection and referral to an ear, nose, and throat specialist for management often are necessary.

Because the incidence of ear malformations is relatively rare—almost 1.3 per 10 000 live births—it is difficult for 1 center to conduct a prospective population study large enough to accumulate sufficient numbers of children with ear anomalies to analyze. Our study was limited by review of only our clinic

TABLE 4. Prevalence of Hearing Loss in Various MCA Syndromes and Ear Anomalies

Syndrome	Percentage With Hearing Impairment
Isolated tag/pit	15–30 ^{1,2}
CHARGE association	85 ¹¹
TBS	44 ¹⁶
OAVS	50 ³⁸
BOR	75 ²²
TCS	55 ³⁹
Nager syndrome	95 ³¹
Miller syndrome	19 ³⁵

patients with ear anomalies, which introduces selection bias in that their ears (or other organ systems) had to be anomalous enough to have been referred for a clinical genetics evaluation. Also, patients who had not undergone renal ultrasonography were excluded, which would affect our calculated incidence of renal malformations; however, our numbers agree with the figures given in review articles of large numbers of children with these syndromes and thereby provide some guidelines for how to decide which children with ear anomalies might benefit from renal ultrasonography.

Ear and kidney development has been characterized in great detail, and we now know that embryologically, ear and kidney primordia arise at different times and develop at different rates. Therefore, the association between ear and kidney anomalies usually is not due to an isolated insult to the embryo that affects both developing structures at the same time. Prolonged embryonic insults, such as those seen in IDMs, may cause defects not just in ears and kidneys but also in many other organ systems. This

reflects the ongoing teratogenesis of toxic metabolites on all developing structures of the embryo. Recent identification of genes that are responsible for BOR and TBS, along with gene expression studies of these genes, has shown that these genes are expressed in developing ear and kidney structures at different times during morphogenesis.³⁷ Temporally and spatially asynchronous gene expression is proving to be a recurring theme in embryogenesis. One example is the nested expression of Hox genes that provide patterning for the medial-lateral axis of the limbs, branchial arches, and somitomeres, all of which arise at different times in development. PAX2 expression, another regulatory gene in the same signaling pathway as EYA1, in optic placodes and nephrogenic tissues is yet another example of this type of expression. The discovery of EYA1 and SALL1 offer insight into why BOR, TBS, and other syndromes demonstrate ear, kidney, and other organ malformations.

ACKNOWLEDGMENTS

This study received support from SHARE's Childhood Disability Center, the Steven Spielberg Pediatric Research Center, the Cedars-Sinai Burns and Allen Research Institute, the Skeletal Dysplasias NIH/NICHD Program Project Grant (HD22657), and the Medical Genetics NIH/NIGMS Training Program Grant (GM08243).

We thank Barbara Lawson for her support with this manuscript.

REFERENCES

- Kugelman A, Hadad B, Ben-David J, Podoshin L, Borochowitz Z, Bader D. Preauricular tags and pits in the newborn: the role of hearing tests. *Acta Paediatr.* 1997;86:170–172
- Kankkunen A, Thiringer K. Hearing impairment in connection with preauricular tags. *Acta Paediatr Scand.* 1987;76:143–146
- Queisser-Luft A, Stolz G, Wiesel A, Schlafer K, Zabel B. Associations between renal malformations and abnormally formed ears: analysis of 32,589 newborns and newborn fetuses of the Mainz Congenital Birth Defect Monitoring System. In: *XXI David W Smith Workshop on Malformation and Morphogenesis*. San Diego, CA. 2000:60
- Steinhart JM, Kuhn JP, Eisenberg B, Vaughan RL, Maggioli AJ, Cozza TF. Ultrasound screening of healthy infants for urinary tract abnormalities. *Pediatrics.* 1988;82:609–614
- Martínez-Frías ML, Bermejo E, Rodríguez-Pinilla E, Prieto L, Frías JL. Epidemiological analysis of outcomes of pregnancy in gestational diabetic mothers. *Am J Med Genet.* 1998;78:140–145
- Kohelet D, Arbel E. A prospective search for urinary tract abnormalities in infants with isolated preauricular tags. *Pediatrics.* 2000;105(5). URL: <http://www.pediatrics.org/cgi/content/full/105/5/e61>
- Leung AK, Robson WL. Association of preauricular sinuses and renal anomalies. *Urology.* 1992;40:259–261
- Harris J, Källen B, Robert E. The epidemiology of anotia and microtia. *J Med Genet.* 1996;33:809–818
- Mastroiacovo P, Corchia C, Botto LD, Lanni R, Zampino G, Fusco D. Epidemiology of and genetics of microtia-anotia: a registry based study on over one million births. *J Med Genet.* 1995;23:453–457
- Brent B. The pediatrician's role in caring for patients with congenital microtia and atresia. *Pediatr Ann.* 1999;6:374–383
- Blake KD, Davenport SLH, Hall BD, et al. CHARGE association: an update and review for the primary pediatrician. *Clin Pediatr.* 1998;37:159–174
- Graham JM. Editorial comment: a recognizable syndrome within CHARGE association: Hall-Hitner Syndrome. *Am J Med Genet.* 2001;99:120–123
- Amiel J, Attié-Bitach T, Marianowski R, et al. Temporal bone anomaly proposed as a major criteria for diagnosis of CHARGE syndrome. *Am J Med Genet.* 2001;99:124–127
- Tellier AL, Cormier-Daire V, Abadie V, et al. CHARGE syndrome: report of 47 cases and review. *Am J Med Genet.* 1998;76:402–409
- Kohlhase J, Wischermann A, Reichenbach H, Froster U, Engel W. Mutations in the SALL1 putative transcription factor gene cause Townes-Brocks syndrome. *Nat Genet.* 1998;18:81–83
- Powell CM, Michaelis RC. Townes-Brocks syndrome. *J Med Genet.* 1999;36:89–93
- Graham JM, Brown FE, Hall BD. Thumb polydactyly as a part of the range of genetic expression for thenar hypoplasia. *Clin Pediatr.* 1987;26:142–148
- Engels S, Kohlhase J, McGaughan J. A SALL1 mutation causes a branchio-oto-renal syndrome-like phenotype. *J Med Genet.* 2000;37:458–460
- Johnson JP, Poskanzer LS, Sherman S. Three-generation family with resemblance to Townes-Brocks syndrome and Goldenhar/oculoauriculovertebral spectrum. *Am J Med Genet.* 1996;61:134–139
- Rollnick BR, Kaye CI, Nagatoshi K, Hauck W, Martin A. Oculoauriculovertebral dysplasia and variants: phenotypic characteristics of 294 patients. *Am J Med Genet.* 1987;26:361–375
- Llano-Rivas I, Gonzalez-del AA, del Castillo V, Reyes R, Carnevale A. Microtia: a clinical and genetic study at the National Institute of Pediatrics in Mexico City. *Arch Med Res.* 1999;30:120–124
- Allanson J. Genetic hearing loss associated with external ear abnormalities. In: Gorlin RJ, Toriello H, Cohen MM, eds. *Hereditary Hearing Loss and Its Syndromes*. New York, NY: Oxford University Press; 1995:76–80
- Vincent C, Kalatzis V, Abdelhak S, et al. BOR and BO syndromes are allelic defects of EYA1. *Eur J Hum Genet.* 1997;5:242–246
- Kumar S, Marres HA, Cremers CW, Kimberling WJ. Autosomal dominant branchio-otic (BO) syndrome is not allelic to the branchio-oto-renal (BOR) gene at 8q13. *Am J Med Genet.* 1998;76:395–401
- Kumar S, Deffenbacher K, Marres HA, Cremers CW, Kimberling WJ. Genomewide search and genetic localization of a second gene associated with autosomal dominant branchio-oto-renal syndrome: clinical and genetic implications. *Am J Hum Genet.* 2000;66:1715–1720
- Reece EA, Homko CJ, Wu YK. Multifactorial basis of the syndrome of diabetic embryopathy. *Teratology.* 1996;54:171–182
- Schaefer-Graf UM, Buchanan TA, Xiang A, Giuliana S, Montoro M, Kjos S. Patterns of congenital anomalies and relationship to initial maternal fasting glucose levels in pregnancies complicated by type 2 and gestational diabetes. *Am J Obstet Gynecol.* 2000;182:313–320
- Ewart-Toland A, Yankowitz J, Winder A, et al. Oculoauricularvertebral abnormalities in children of diabetic mothers. *Am J Med Genet.* 2000;90:303–309
- Jones KL, ed. *Smith's Recognizable Patterns of Human Malformation*, 5th Ed. Philadelphia, PA: WB Saunders; 1997:250–251
- Allanson J. Genetic hearing loss associated with external ear abnormalities. In: Gorlin RJ, Toriello H, Cohen MM, eds. *Hereditary Hearing Loss and Its Syndromes*. New York, NY: Oxford University Press; 1995:62–64
- McDonald MT, Gorski JL. Nager acrofacial dysostosis. *J Med Genet.* 1993;30:779–782
- Pfeiffer RA, Stoess H. Acrofacial dysostosis (Nager syndrome): synopsis and report of a new case. *Am J Med Genet.* 1983;15:255–260
- Halal F, Herrmann J, Pallister P, Opitz J, Desgranges MF, Grenier G. Differential diagnosis of Nager acrofacial dysostosis syndrome: report of four patients with Nager syndrome and discussion of other related syndromes. *Am J Med Genet.* 1983;14:209–224
- Kawira EL, Weaver DD, Bender HA. Acrofacial dysostosis with severe facial clefting and limb reduction. *Am J Med Genet.* 1984;17:641–647
- Ogilvy-Stuart AL, Parsons AC. Miller syndrome (postaxial acrofacial dysostosis): further evidence for autosomal recessive inheritance and expansion of the phenotype. *J Med Genet.* 1992;28:695–700
- Potter EL. Bilateral renal agenesis. *J Pediatr.* 1946;29:68
- Kalatzis V, Sahly I, El-Amraoui A, Petit C. EYA1 expression in the developing ear and kidney: towards the understanding of the pathogenesis of branchio-oto-renal (BOR) syndrome. *Dev Dyn.* 1998;213:486–499
- Allanson J. Genetic hearing loss associated with external ear abnormalities. In: Gorlin RJ, Toriello H, Cohen MM, eds. *Hereditary Hearing Loss and Its Syndromes*. New York: Oxford University Press; 1995:69–73
- Pinsky L. Penetrance and variability of major malformation syndromes associated with deafness. *Birth Defects Orig Artic Ser.* 1979;15(suppl 5B):207–226